

SEVERE CORNEAL NEUROTROPHIC ULCER FOLLOWING UNCOMPLICATED CATARACT SURGERY: A CASE REPORT

Derdera E. 1 , Kolas D. 1 , Chroni M. 1 , Alexopoulos P. 2 , Kontadakis G. 1

1. Department of Ophthalmology, Pammakaristos Hospital of Divine Providence, Athens, Greece

2. Department of Ophthalmology, State University of New York (SUNY) Health Sciences University, New York, US

Purpose

To report a case of severe neurotrophic corneal ulceration occurring shortly after uncomplicated cataract surgery in a high-risk patient and to highlight the importance of early recognition and prompt management.

Introduction

Corneal neurotrophic ulcers represent a rare but potentially sight-threatening complication following cataract surgery. Neurotrophic keratopathy results from impairment of corneal sensory innervation, leading to decreased corneal healing capacity and epithelial breakdown. Several predisposing factors may contribute to the development of postoperative neurotrophic ulcers, including diabetes mellitus, severe dry eye disease, ocular surface inflammation, and the postoperative use of topical non-steroidal anti-inflammatory drugs (NSAIDs).

Early diagnosis and aggressive treatment are essential to prevent corneal

Case Presentation

An 82-year-old female patient presented with bilateral advanced cataracts. Preoperative examination revealed severe dry eye disease, mild chronic blepharitis, subtle subepithelial corneal opacities and reduced corneal sensitivity.

The patient underwent uneventful phacoemulsification with intraocular lens implantation in the left eye. Postoperatively, she was treated with topical antibiotic-steroid combination drops, topical NSAIDs and preservative-free lubricating drops.

The first postoperative day examination was unremarkable.

Seven days after surgery the patient reported sudden painless visual deterioration. Slit-lamp examination revealed a large corneal epithelial defect extending from the main surgical incision toward the central cornea, associated with localized superficial corneal melting both at the incision site and centrally. A positive Seidel test was observed. (figure 1)

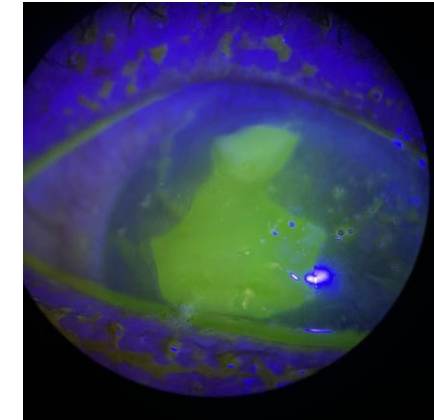
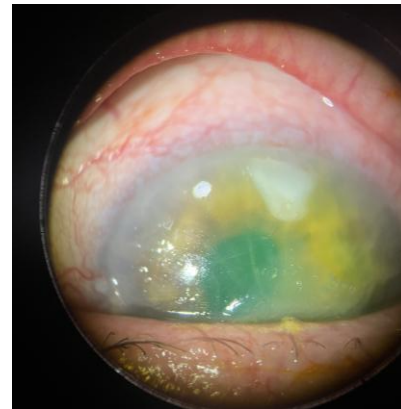
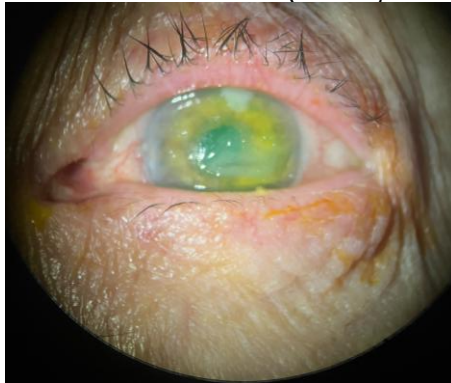


Figure 1

Corneal ulcer with epithelial defect extending from the surgical incision to the central cornea (postoperative day 7).

Corneal scrapings were obtained for microbiological cultures. Treatment was initiated immediately with topical moxifloxacin, autologous serum eye drops, preservative-free lubricants and oral doxycycline. Topical NSAIDs and corticosteroids were discontinued. Autologous serum eye drops were prepared from 20 ml of the patient's peripheral blood, which was centrifuged at 3000 rpm for 15 minutes. The separated serum was diluted to obtain 20% autologous serum drops and administered frequently throughout the day.

Microbiological cultures were negative and the clinical presentation was consistent with neurotrophic corneal ulceration. A therapeutic bandage contact lens was applied. The Seidel test became negative within 48 hours, and progressive epithelial healing was observed. Complete corneal re-epithelialization was achieved within 3 weeks under treatment. (figure 2)

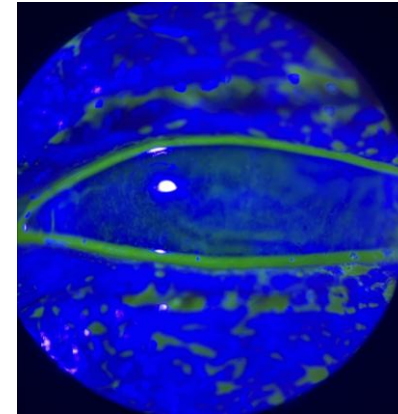
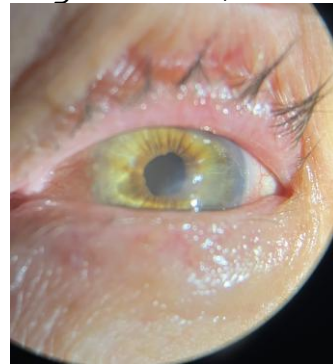


Figure 2

Significant corneal healing with complete epithelialization six weeks after treatment initiation.

Discussion

Corneal neurotrophic ulceration is a potentially devastating complication that may occur after cataract surgery in high-risk patients. NSAID use combined with diabetes related neurotrophic changes and severe dry eye disease were considered major