

Corneal perforation due to neglected ocular trauma: diagnostic and therapeutic challenges

E. Amaxilati¹, F. Styllas¹, P. Ioannidis¹, G. Tsiropoulos¹, D. Giannoulis¹, D. Mikropoulos¹

1. First Department of Ophthalmology, AHEPA University Hospital, School of Medicine, Aristotle University of Thessaloniki, Thessaloniki, Greece

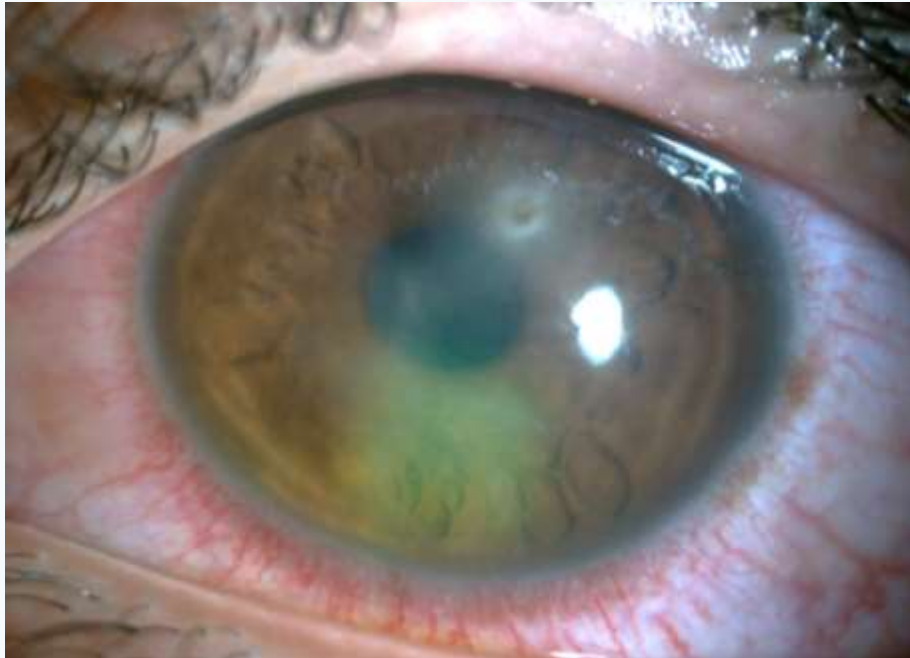The authors declare that they have no conflicts of interest to disclose.

No external funding was received for this work.

Patient & Clinical Findings

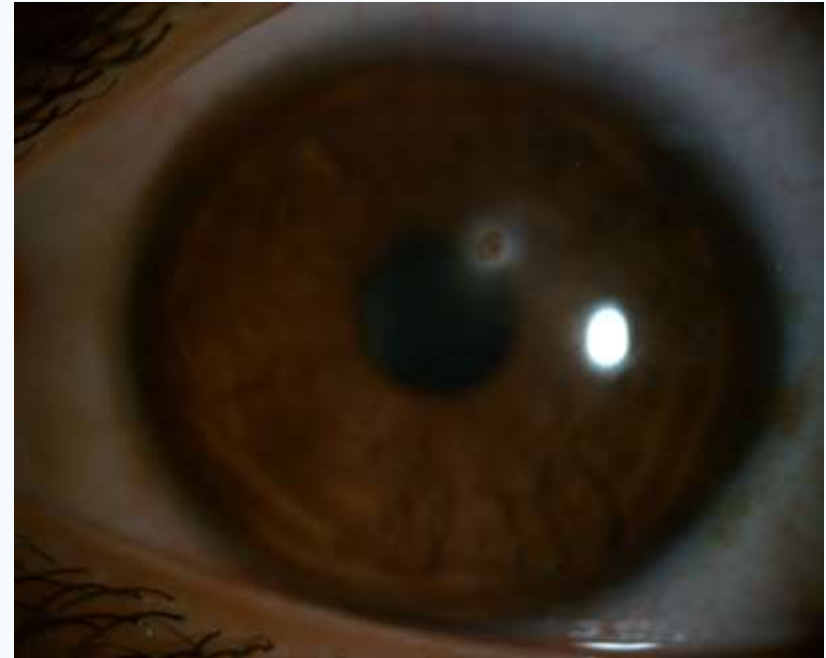Patient Summary

- Male, 22 years old
- Left ocular pain
- Ocular trauma 1.5 months earlier
- On hourly topical levofloxacin; therapeutic contact lens in place



Key Findings (Slit-lamp)

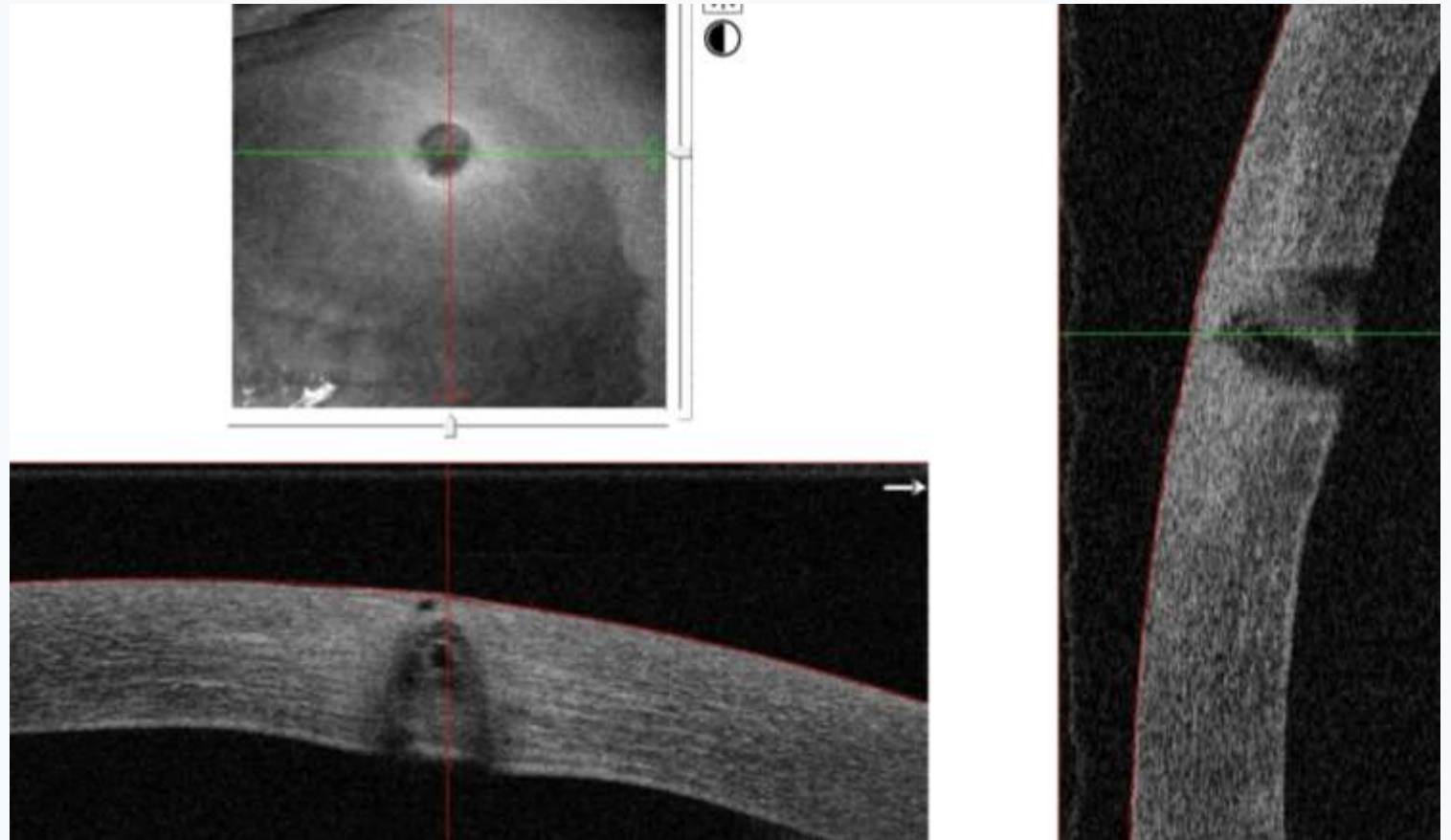
- Visual acuity: counting fingers (left eye)
- Descemet's membrane folds
- Subepithelial and stromal opacities
- Metallic intracorneal foreign body
- Marked corneal thinning



Imaging & Decision-making

Imaging work-up

- Slit-lamp photography and anterior segment OCT documented depth and extent of thinning.
- Imaging informed risk assessment and therapeutic planning.



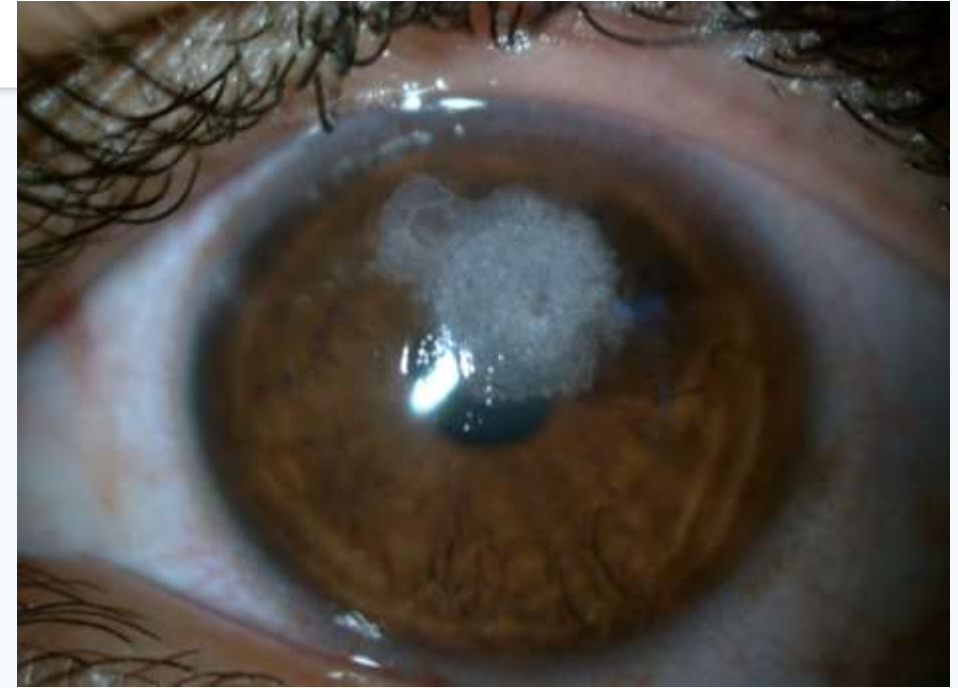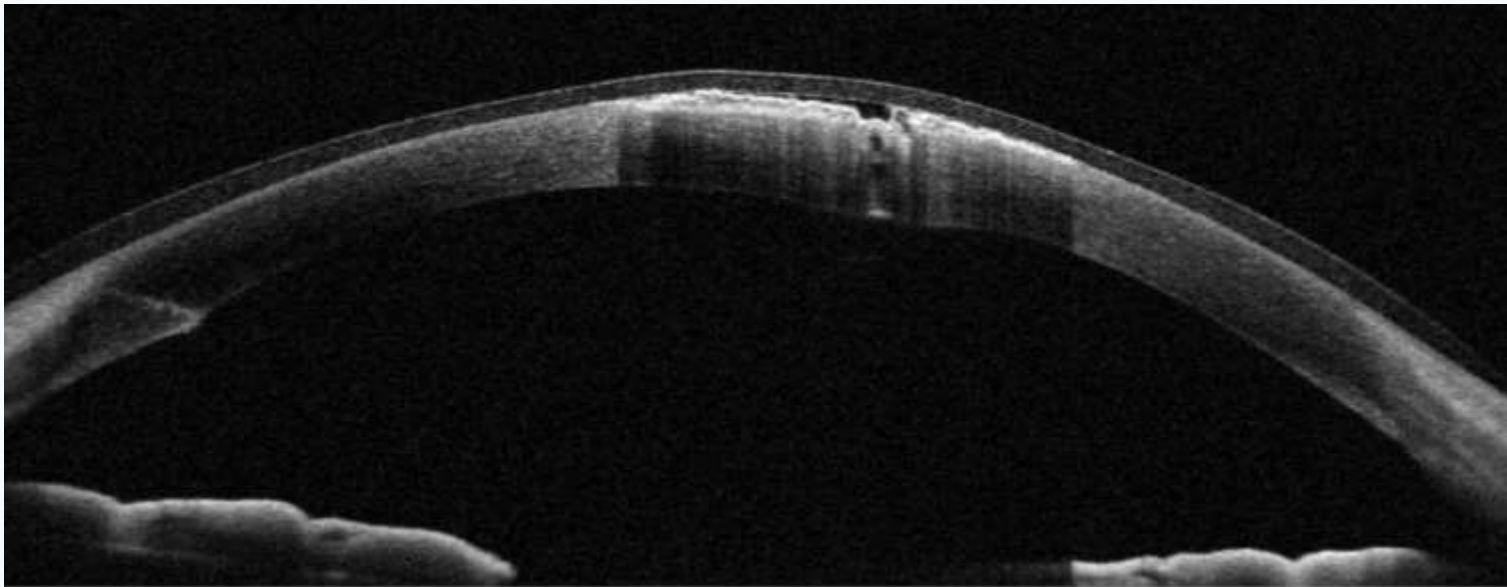
Decision points

- Admit for intensive therapy when thinning is advanced and follow-up is uncertain.
- Re-examine frequently; a positive Seidel test indicates active aqueous leak / high perforation risk.
- Escalate to surgical management: foreign body removal + tissue adhesive when appropriate.

Treatment & Outcome

Intervention

- Admission and intensive topical antibiotic therapy
- Positive Seidel test on repeat exam indicated impending perforation
- Surgical foreign body removal with cyanoacrylate glue application



Outcome

- Anterior chamber: quiet, well-formed and watertight post-operatively
- Visual acuity improved to 3/10 (uncorrected)

Discussion & Take-home Messages

Discussion highlights

- Neglected intracorneal metallic foreign bodies may show minimal symptoms initially, yet progressively weaken the cornea.
- Combining slit-lamp findings with AS-OCT improves detection of advanced thinning and supports timing of intervention.
- Tissue adhesive is a minimally invasive option to stabilize severe thinning or seal small leaks, potentially avoiding emergency keratoplasty.

Take-home messages

- Delayed corneal trauma can conceal an intracorneal foreign body and progressive thinning.
- AS-OCT helps quantify thinning and supports timely escalation to surgical intervention.
- Cyanoacrylate glue can stabilize severe thinning / small leaks and preserve globe integrity.

Practical approach

