

Combined use of intracorneal ring segments and specialty hydrogel contact lenses in the optical correction of keratoconus

Lefteris Karageorgiadis¹, Nikos Vasileiou², Asterios Gratsonidis³

1. Eyeart fitting center, Thessaloniki, Greece
2. Eyeart Laboratories, Thessaloniki, Greece
3. Private medical practice, Drama, Greece

Disclaimer

1. EYEART's fitting center owner
2. EYEART Laboratories, cowner

Patient history

Patient: 40 yrs old Female

Ocular history: Advanced keratoconus

Surgical treatment:

Intracorneal segments OO

PRE OPERATIVE DATA:

Pre operation Rx

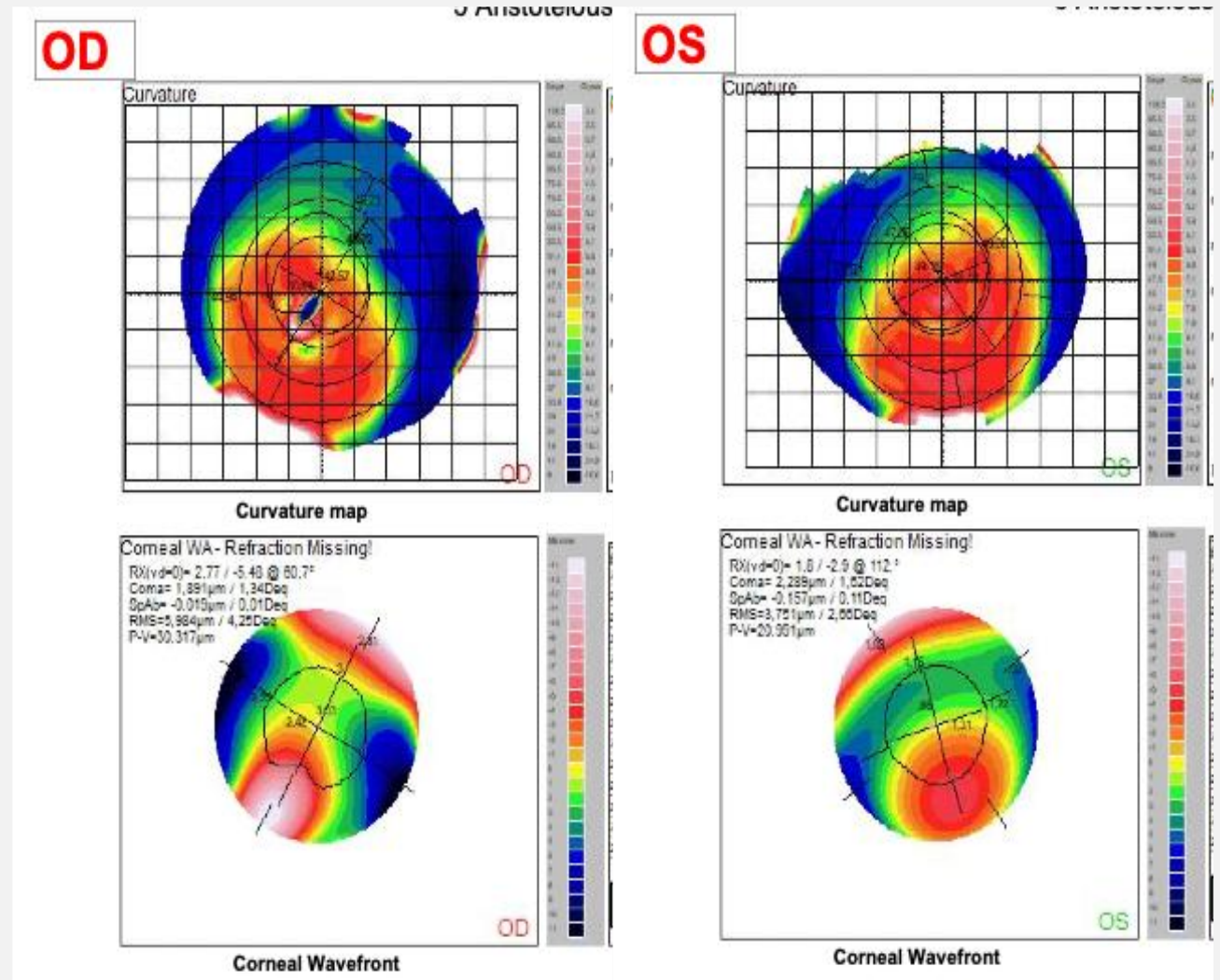
RE -9.00 -5.00 x 60 VA 2/10

LE -15.00 -4.50 x 110 VA 3/10

Scleral lenses have been worn

RE VA 6/10

LE VA 5/10



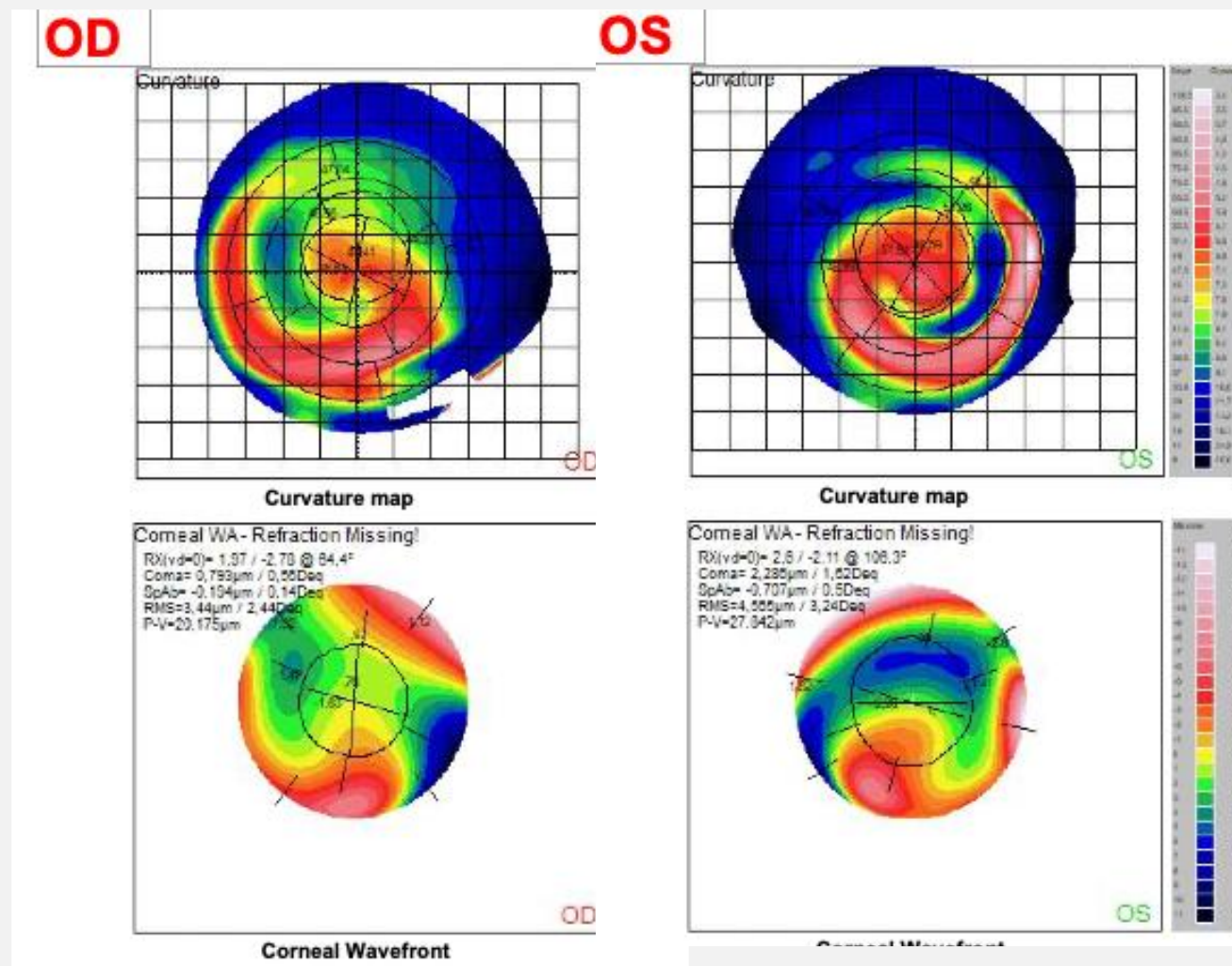
Post surgical anterior corneal astigmatism

7 days post operation

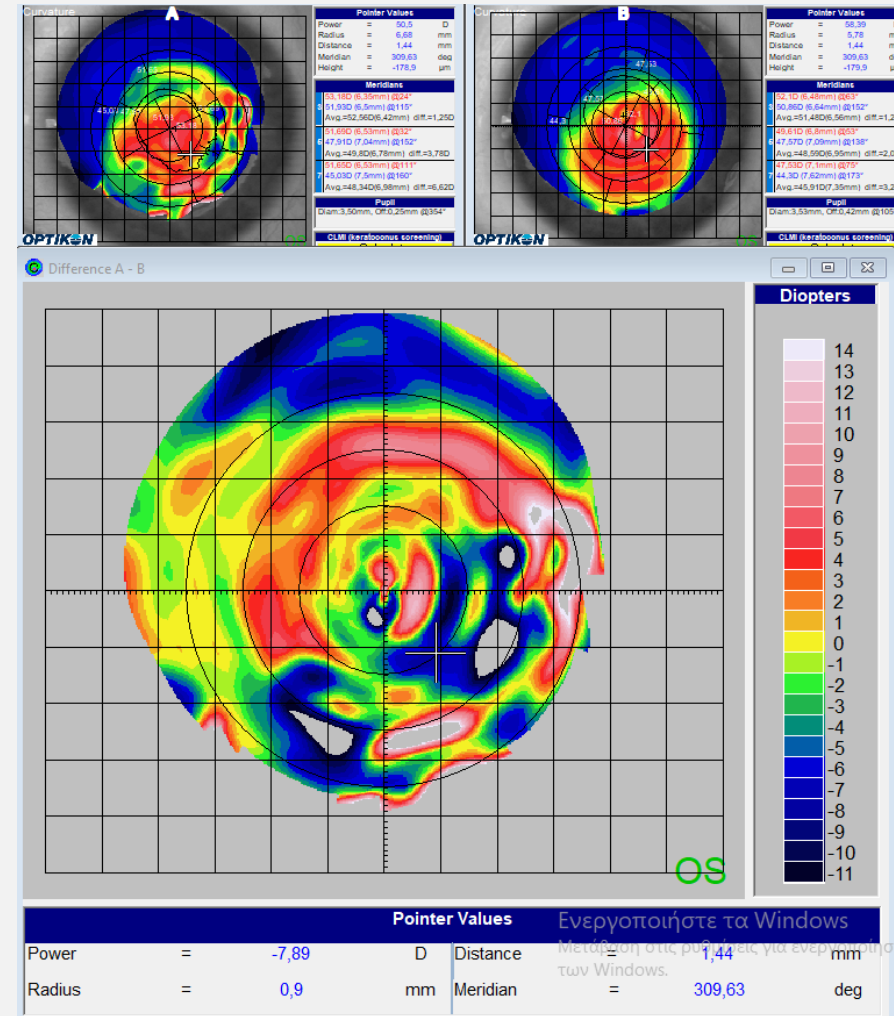
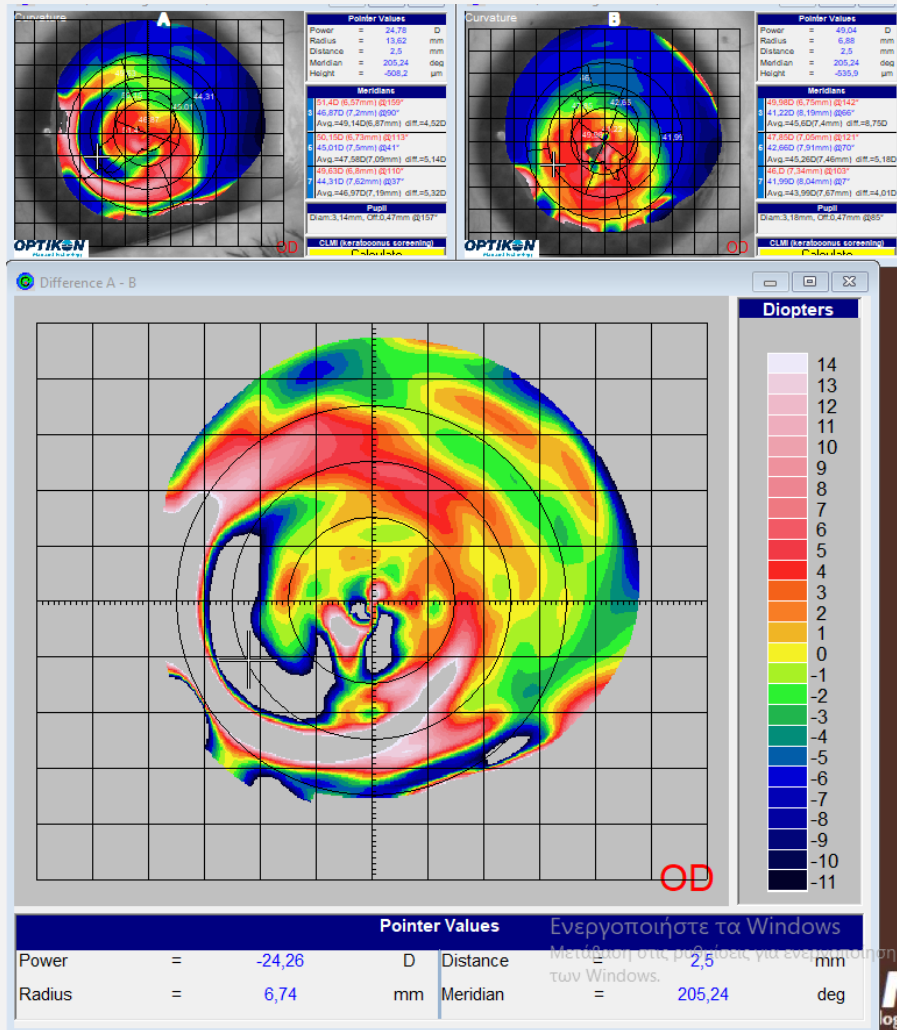
Anterior corneal surface
blending:

RE Anterior corneal surface
topography astigmatism
reduction: 2.00 D

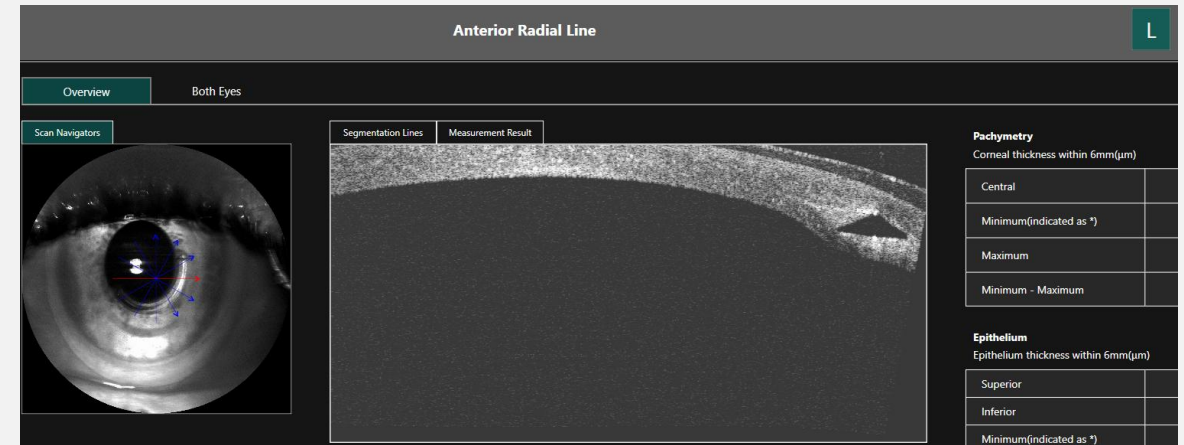
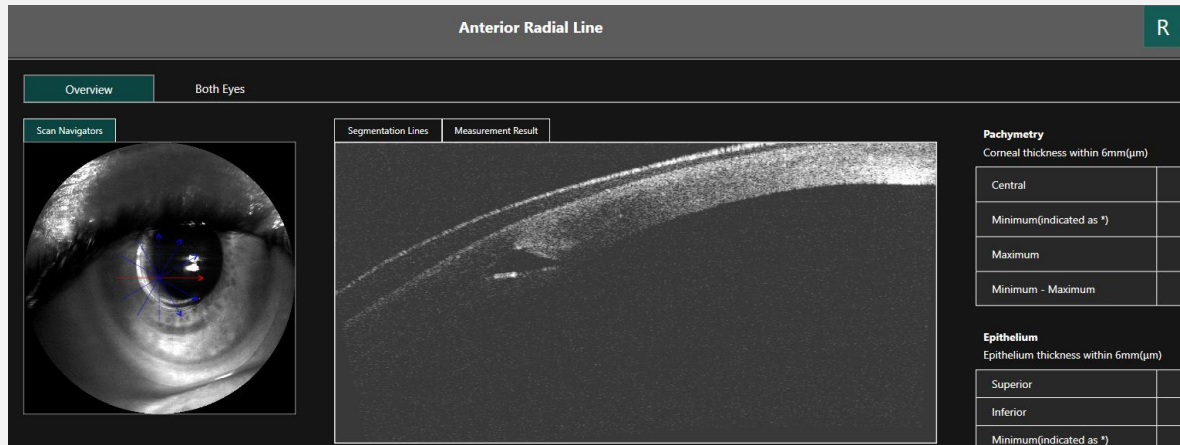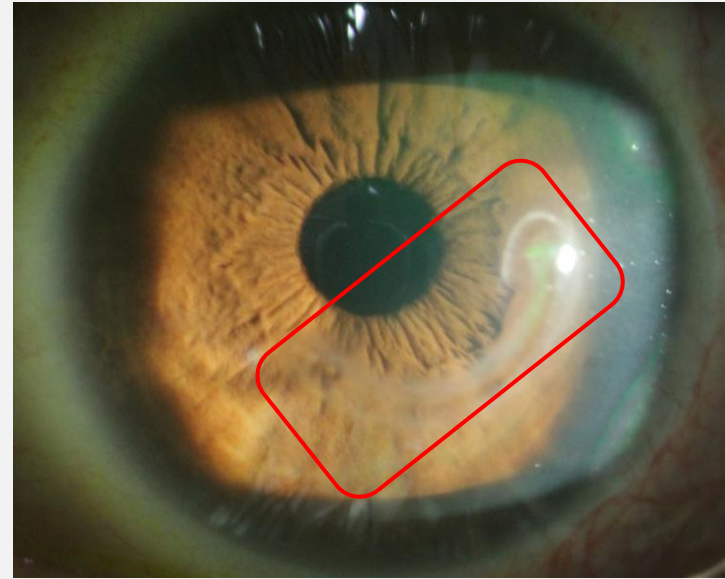
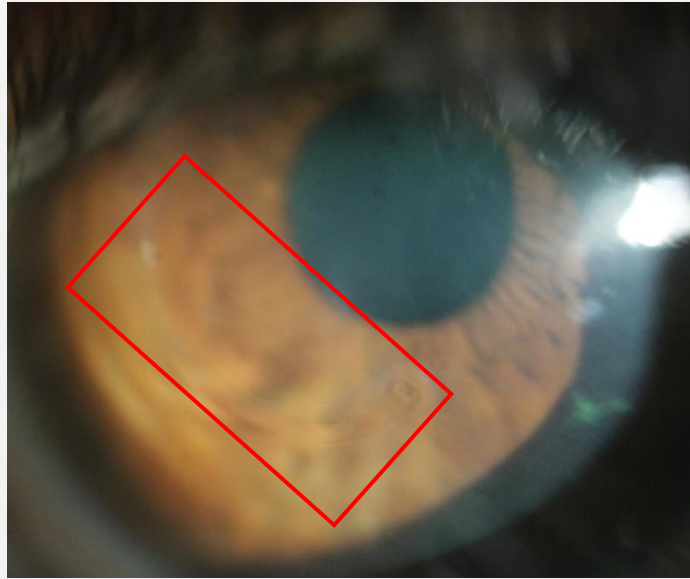
LE Anterior corneal surface
topography astigmatism
reduction: 0.80 D



Post surgical localised flattening



Intracorneal segments in situ



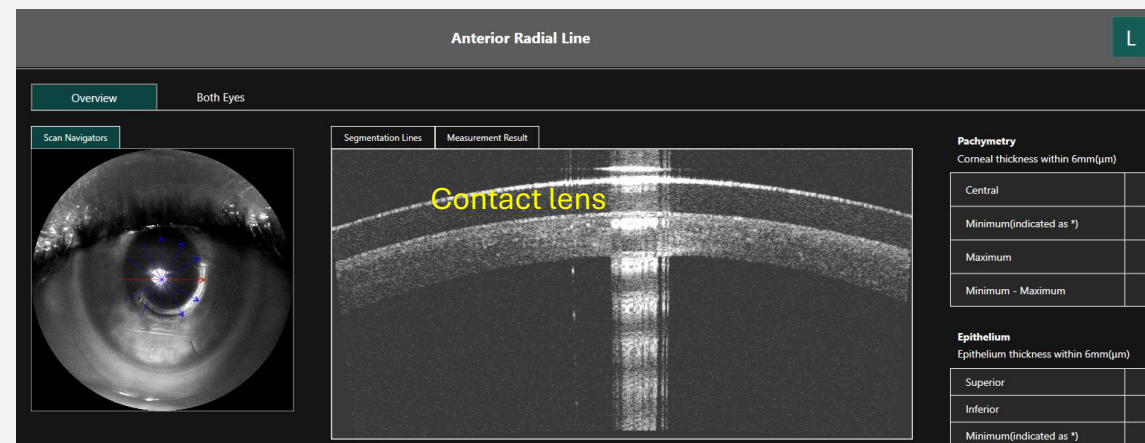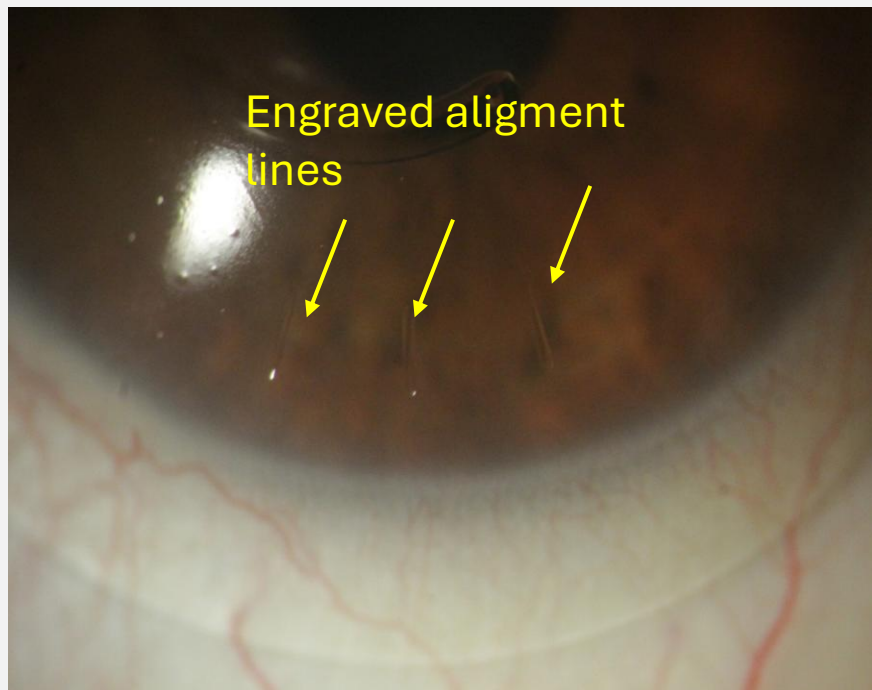
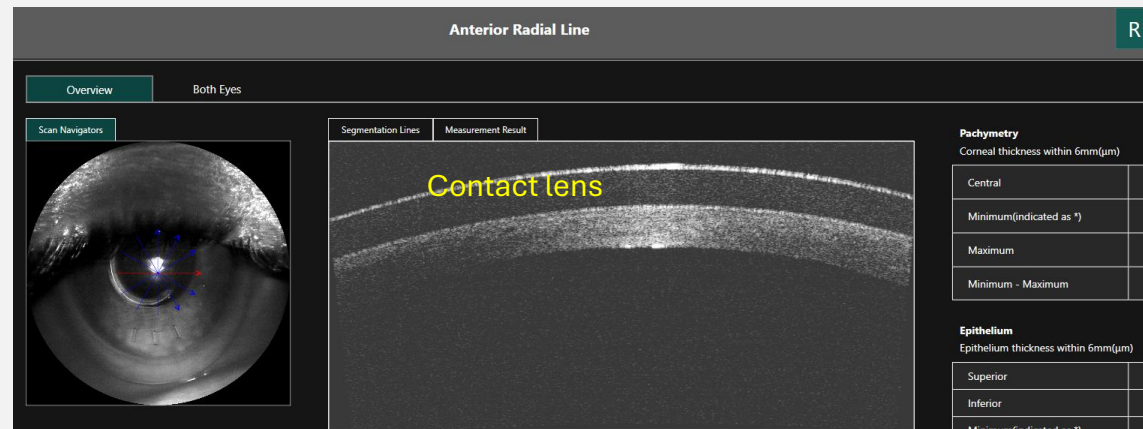
Scope:

Provide functional vision post surgically

Specialty hydrogel contact lenses for keratoconus:

RE sph -11.75 cyl -2.00 axis 80 VA 5/10-

LE sph -15.25 cyl -0.50 axis 130 VA 4/10+



Discussion

1. Optical correction of keratoconus may combine surgical and non-surgical procedures
2. Combination of hydrogel lenses for keratoconus, following intracorneal segments insertion, may be used as soon epithelium and corneal physiology is stable.
3. Corneal flattening may continue, due to low soft contact lens material modulus and appropriate fitting
4. Optical performance/visual acuity may reach that of scleral lenses, due to corneal segment shape blending/flattening effect.